

Subclinical celiac disease with cerebellar ataxia

Tugba Tunc¹, Esra OKUYUCU¹, Serap UCLER¹, Tolga SONMEZ¹, Ozlem COSKUN¹, Eyup SELVI² and Levent E. INAN¹

¹Ministry of Health, Ankara Research and Training Hospital Department of Neurology, Ankara, Turkey

²Ministry of Health, Ankara Research and Training Hospital Department of Gastroenterology, Ankara, Turkey

Abstract

We report an unusual case of celiac disease with cerebellar ataxia. Gastrointestinal signs and malabsorption were not found in this patient. We suggested that celiac disease should be taken into consideration in differential diagnosis of patients with cerebellar ataxia with unknown etiology.

Key words : Celiac disease ; cerebellar ataxia ; tremor.

Introduction

Celiac disease is a malabsorption syndrome, characterized by abdominal distension, flatulence, diarrhea, steatorrhea, weight loss, intolerance to gluten protein, and structural abnormalities of small bowel mucosa (Ghezzi *et al.*, 1997 ; Hanagasi *et al.*, 2001 ; Hermaszewski *et al.*, 1991). The disease has a hereditary nature (Hanagasi *et al.*, 2001). Gluten and gluten products have a toxic effect on intestinal mucosa, resulting in abnormal intestinal mucosal function. It is suggested that, gluten and gluten breakdown products cause the immunological reactions in the intestinal mucosa (Ghezzi *et al.*, 1997).

Antiendomysial, gliadin, reticulin antibodies and IgA anti tissue transglutaminase are found in patients with the disease (Wills *et al.*, 2000, Kristoferitsch *et al.*, 1987). Lymphocytic infiltration, villous atrophy and crypt hyperplasia can be detected in small bowel biopsy. (Fung *et al.*, 2000).

In celiac disease, neurologic involvement occurs in 8% to 10% of the patients (Pellechia *et al.*, 2002). The most common neurological manifestations are cerebellar ataxia (Luostarinen *et al.*, 1999), myelopathy, brainstem encephalitis, progressive multifocal leukoencephalopathy, encephalopathy, dementia, seizures, progressive myoclonic ataxia, peripheral neuropathy (Ghezzi *et al.*, 1997) and internuclear ophthalmoplegia (Wills, 2000). Neurological findings can be the sole clinical manifestation of celiac disease without malabsorption and other gastrointestinal system abnormalities (Pellechia *et al.*, 2002).

We present here a patient with cerebellar ataxia, in the absence of gastrointestinal symptoms and malabsorption with serological and pathologic evidence of celiac disease.

Case report

This 44-year-old-man was first admitted to our hospital in December 2002. He presented with a 2 years history of gait difficulty and tremor on his arms. Severity of the symptoms was progressively increased during the last one year. There was no history of chronic alcohol or drug abuse nor were neurological disorders known among his relatives. In neurological examination he was alert and fully oriented. Although he had a cerebellar syndrome, his cranial nerves were normal. Muscle strength and sensory examination were normal. Plantar reflexes and tendon reflexes were normal. A cerebellar syndrome with gait ataxia, intention tremor and dysarthric speech was found.

Routine blood examination, protein electrophoresis, urine analysis, thyroid and parathyroid function tests, serum copper, ceruloplasmin, total copper in 24 h urine, serum levels of vitamin B12, folate and vitamin E, pyruvate, lactate levels in serum, serologic tests in serum, brucella agglutination test, faeces examination were normal. Kayser-Fleischer ring were not found. Cerebrospinal fluid (CSF) investigations revealed high protein levels. Oligoclonal bands were positive in CSF. Cranial CT was normal. Abdominal ultrasonography revealed the presence of hepatosteatosis. Nerve conduction studies, electroencephalography, electromyography, brainstem evoked potentials, visual evoked potentials, tibial somatosensory evoked potentials were normal. Cranial magnetic resonance imaging (MRI) showed mild hyperintensity in medulla oblongata, pons, periaqueductal area of mesencephalon, bilateral superior cerebellar peduncle, adjacent to bilateral posterior part of the lateral ventricle, left to the splenium of the corpus callosum, right temporal region, periventricular white matter and subcortical white matter (Fig. 1, 2). Pathological contrast enhancement was not found.

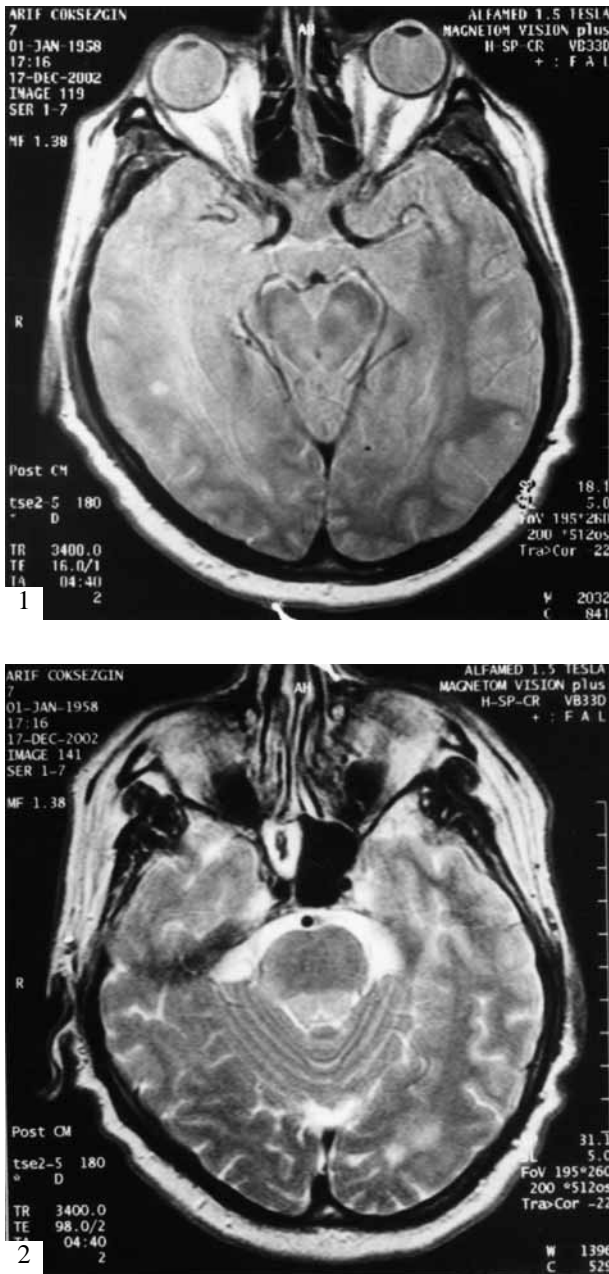


FIG. 1, 2. — Axial MRI images of the brain

According to the clinical manifestation and MRI images, we examined the serologic markers of gluten enteropathy. Antigliadin IgA and antigliadin IgG were positive (antigliadin IgA : 28.4 and antigliadin IgG : 40.26). ELISA techniques were used for measuring the levels of the antibodies. Other antibodies such as antinuclear antibodies and anti DNA antibodies were negative. The small bowel biopsy revealed intestinal lymphangiectasia, and lymphocytic inflammation. The villous atrophy and crypt hyperplasia can not be found in small bowel biopsy. MMSE score was 27.

According to the clinical manifestation and laboratory results consistent with gluten enteropathy of the patient was diagnosed to have celiac disease.

He was treated with a gluten free diet. Gabapentine was used for this tremor. However, his cerebellar ataxia and neurological manifestations did not improve.

Discussion

Cooke *et al.*, in 1966, reported 16 patients with neurological complications of celiac disease (Cooke *et al.*, 1966). Approximately 10% of patients with celiac disease characterized by diarrhea, malabsorption and weight loss are complicated with neurological abnormalities, especially cerebellar ataxia (Combarros *et al.*, 2000). The mechanism of the neurological complications is not definite (Pellecchia *et al.*, 1999). Malabsorption was thought to be the cause of neurological complication. However, nutritional, toxic and immunologic abnormalities were suggested as causes of the neurological involvement of the disease. Abnormal immunological reactions may be responsible for the occurrence of the neurological complications (Hanagası *et al.*, 2001). Antigliadin antibodies are suggested to be neurotoxic (Pellecchia *et al.*, 1999). Hadjivassiliou *et al.* reported a series of patients with neurological complications of celiac disease. In these patients there were positive correlations between the duration of the ataxia and cerebellar atrophy. It is suggested that the continuous intake of gluten and its products may be harmful to cerebellar cells in gluten sensitive patients (Hadjivassiliou *et al.*, 1998). In recent studies, idiopathic cerebellar ataxia without abdominal symptoms and signs that had a serologic positivity with or without histological evidence of celiac disease has been reported (Combarros *et al.*, 2000). The cerebellar ataxia is the most common symptom of the neurologically complicated celiac disease (Hadjivassiliou *et al.*, 1998). As in our patient, sometimes cerebellar ataxia can be the main clinical manifestation without any symptoms of gastrointestinal disease or malabsorption. Recently, some studies showed celiac disease can be found in patients without gastrointestinal signs, and neurological symptoms may be the first manifestations of the disease (Luostarinen *et al.*, 1999). Certainly, patients must be evaluated for hereditary, inflammatory, paraneoplastic, toxic or metabolic cerebellar disorders. In our patient, we excluded all the reasons above and we confirmed the diagnosis by presence of the antigliadin antibodies in the serum. The small bowel mucosa can be normal in individuals, as in our patient, whom has serologically evident gluten sensitivity (Combarros *et al.*, 2000). In this condition, clinical and histological remission is achieved with gluten free diet (Luostarinen *et al.*, 2003). However the effectiveness of gluten free diet in treatment of the neurological complications of the disease is not clear. Some reports showed the clinical and electrophysi-

ological improvement in neurological complications of celiac disease (Pellecchia *et al.*, 1999). However cerebellar ataxia of our patient did not improve with gluten free diet.

In conclusion, although gluten sensitivity is known as malabsorption syndrome, the neurological symptoms may be the first manifestations of the disease. Therefore, individuals with ataxia, polyneuropathy and other neurological abnormalities of unknown etiology should be investigated for celiac disease.

REFERENCES

- COMBARROS O., INFANTE J., LOPEZ-HOYOS M., BARTOLOME M. J., BERCIANO J., CORRAL J., VOLPINI V. Celiac disease and idiopathic cerebellar ataxia. *Neurology*, 2000, **54** (12) : 2346.
- COOKE W. T., THOMAS SMITH W. Neurological disorders associated with adult coeliac disease. *Brain*, 1966, **89** : 683-722.
- FUNG V. S. C., DUGGINS A., MORRIS J. G. L., LORENTZ I. T. Progressive myoclonic ataxia associated with celiac disease presenting as unilateral cortical tremor and dystonia. *Movement Disorders*, 2000, Vol 15, No 4 : 732-734.
- GHEZZI A., FILIPPI M., FALINI A., ZAFFARONI M. Cerebral involvement in celiac disease : A serial MRI study in a patient with brainstem and cerebellar symptoms. *Neurology*, 1997, **49** : 1447-1450.
- HADJIVASSILIOU M., GRUNEWALD R. A., CHATTOPADHYAY A. K., DAVIES-JONES G. A. B., GIBSON A., JARRATT J. A., KANDLER R. H., LOBO A., POWELL T., SMITH C. M. L. Clinical, radiological, neurophysiological, and neuropathological characteristics of gluten ataxia. *Lancet*, 1998, **325** : 1582-1585.
- HANAGASI H. A., GUROL E., SAHIN H. A., EMRE M. Atypical neurological involvement associated with celiac disease. *European Journal of Neurology*, 2001, **8** : 67-69.
- HERMASZEWSKI R. A., RIGBY S., DALGLEISH A. G. Coeliac disease presenting with cerebellar degeneration. *Postgrad. Med. J.*, 1991, **67** : 1023-1024.
- KRISTOFERITSCH W., POINTNER H. Progressive cerebellar syndrome in adult coeliac disease. *J. Neurol.*, 1987, **234** : 116-118.
- LUOSTARINEN L., HIMANEN S. L., LUOSTARINEN M., COLLIN P., PIRTILLA T. Neuromuscular and sensory disturbances in patients with well treated coeliac disease. *J. Neuro Neurosurg. Psychiatry*, 2003, **74** : 490-494.
- LUOSTARINEN L., PIRTILLA T., COLLIN P. Coeliac disease presenting with neurological disorders. *Eur. Neurol.*, 1999, **42** : 132-135.
- PELLECHIA M. T., AMBROSSIO G., SALVATORE E., VITALE C., DE MICHELE G., BARONE P. Possible gluten sensitivity in multiple system atrophy. *Neurology*, 2002, **59** (7) : 1114-1115.
- PELLECHIA M. T., SCALA R., FILLA A., DE MICHELE G., CIACCI C., BARONE P. Idiopathic cerebellar ataxia associated with celiac disease : lack of distinctive neurological features. *J. Neurol. Neurosurg. Psychiatry*, 1999, **66** : 32-35.
- PELLECHIA M. T., SCALA R., PERRETTI A., DE MICHELE G., SANTORO L., FILLA A., CIACCI C., BARONE P. Cerebellar ataxia associated with sub-clinical celiac disease responding to gluten free diet. *Neurology*, 1999, **53** : 1606-1608.
- WILLS A. J. The neurology and neuropathology of coeliac disease. *Neuropathology and Applied Neurobiology*, 2000, **26** : 493-496.

T. TUNC, M.D.,
38. Cadde 3 / 21 Çukurambar Yüzüncüyıl
Ankara (Türkiye).
E-mail : tugbatunc@yahoo.com.